Preoperative Gonadotropin Releasing Hormone (GnRH) Agonist Treatment for Giant Endometrial Polyp: A Case Report

Richard G. Malicdan, MD
Sheryl B. Carullo, MD FPOGS, FPSRM

Baguio General Hospital and Medical Center

Abstract:

Endometrial polyps are localized outgrowths of glands and stroma within the endometrium primarily caused by hyperestrogenism. They are common causes of abnormal uterine bleeding and infertility by altering the endometrial surface. Polyps may be small, large measuring more than 1 centimeter, or giant up to more than 4 centimeters in size. Large and giant polyps are very rare and prone to oncologic malformation, thus biopsy is recommended. Endometrial resection with biopsy is the gold standard treatment, but could be difficult since giant endometrial polyps occupy the entire endometrial cavity resulting to morbidity and failure on hysteroscopy. Limited case reports and studies have used Gonadotropin Releasing Hormone (GnRH) Agonist as preoperative therapy to decrease polyps size prior to hysteroscopic resection. Knowing that GnRH agonists cause a hypoestrogenic state and endometrial polyps are primarily caused by hyperestrogenism, in this case report, it was utilized as treatment prior to hysteroscopic resection of a giant endometrial polyp.

Case:

This is the case of a 27-year-old, nulligravid, who presented with a 9- month history of heavy menstrual bleeding with post coital bleeding and abdominal enlargement. Physical examination revealed a pinkish polypoid fleshy mass protruding from the cervical os measuring 2x2 centimeters. The uterus was enlarged to 17 weeks size with no adnexal masses. Ultrasound revealed an enlarged uterus measuring 16cm and an endometrial polyp extending to the endocervix measuring 12 cm. She underwent biopsy which revealed an endometrial polyp. She was given a total of 6 doses of GnRH agonist every 28 days to possibly reduce polyp size since hysteroscopy was deemed technically difficult. An add-back therapy of Tibolone and calcium + vitamin D were given to prevent vasomotor symptoms and bone loss, respectively. Repeat ultrasound after treatment revealed a 73% decrease in uterine volume. The endometrial stripe was 2.76cm with multiple cystic structures within. Hysteroscopic resection was done. Intraoperatively, the previously prolapsing endometrial mass was no longer seen. The uterine depth was 8 centimeters. Bilateral fallopian tube ostia were not visualized. Within the endometrium is a fleshy polypoid mass measuring 2.7 x 2 x 2 centimeters attached at the posterofundal area. There were areas of increased vascularity with intrauterine adhesions surrounding the polyp. Histopathologic examination was consistent with an endometrial polyp. Final diagnosis was abnormal uterine bleeding secondary to giant endometrial polyp; status post hysteroscopic resection; status post 6 doses of GnRH agonist. She was advised continuous treatment with low dose estradiol valerate daily with overlap of progesterone for the last 5 days of each month for 3 months to prevent intrauterine adhesions. A second look hysteroscopy was done after 3 months revealing no adhesions nor polyp remnant.

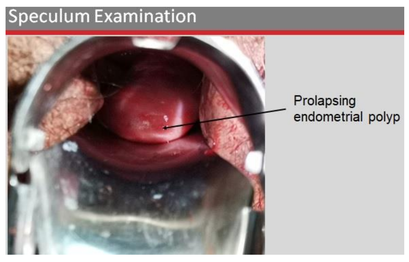

Speculum examination on initial consultation showing a 2x2 centimeter fleshy polypoid mass protruding through the cervical os.

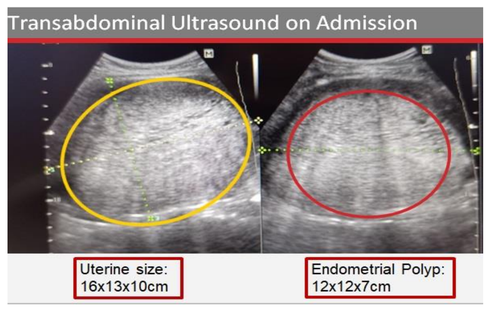

Transvaginal ultrasound on initial admission which revealed an enlarged uterus and a giant endometrial polyp measuring 12.35 x 12.02 x 7.27 cm occupying the entire endometrial cavity.

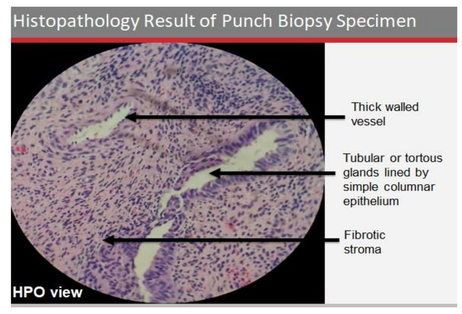

Punch biopsy of the prolapsing endometrial mass, which showed sections with polypoid tissue fragments composed of tubular or tortuous glands lined by simple columnar epithelium. These are surrounded by fibrotic stroma with scattered thick-walled vessel which was consistent with an endometrial polyp.

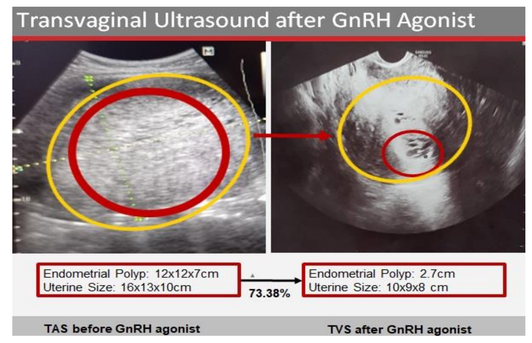

Transvaginal ultrasound after 6 doses of GnRH agonists which revealed a uterine size of 10.82 x 9.39 x 8 cm from a previous 16.96 x 13.16 x 10.48 cm. The endometrial stripe was 2.76 cm with cystic spaces within from a previous 12.35 x 12.02 x 7.27 centimeter polyp size.

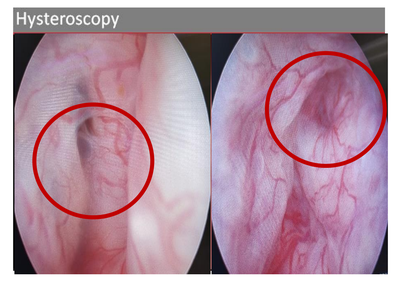

Diagnostic hysteroscopy view of the fundal area of the uterus showing ostia of the bilateral fallopian tubes

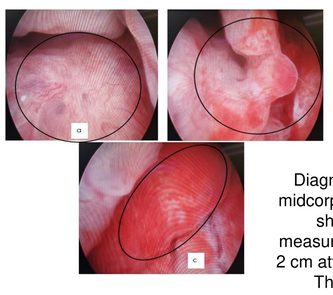

Diagnostic hysteroscopy view of the midcorpus and fundal area of the uterus showing an endometrial mass measuring 2.7 x 2 x 2 cm with a base of 2 cm attached at the posterofundal area. The endometrial mass and the midcorpus area are hypervascular.

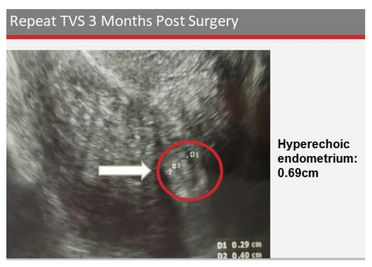

No adhesions nor polyp remnant.

Conclusion:

Giant endometrial polyps are exceedingly rare and are more common for oncologic transformation. The best diagnostic and therapeutic modality is through hysteroscopy. However, giant endometrial polyps hinder easy access to the uterine cavity and increase the possibility of uterine perforation and fluid overload. To prevent this, a neoadjuvant treatment of GnRH agonist was given in the case presented to decrease polyp size prior to surgical intervention. There are limited literatures supporting the use of GnRH agonists as pretreatment for large or giant polyps prior to hysteroscopic resection and biopsy. Based on this case report and review of literature, GnRH agonist might be an effective preoperative therapy for giant endometrial polyps prior to hysteroscopic resection to ensure adequate visibility and resection of the mass and to prevent possible morbidities.

References:

1. Lobo et.al. (2017). Comprehensive Gynecology. Philadelphia: Elsevier, 391 p.

2. Nijkang N, Anderson L, Markham R, Manconi F. Endometrial polyps: Pathogenesis, sequelae and treatment. SAGE Open Medicine. 2019;7:205031211984824.

3. Yang J, Chen C, Chen S, Yang Y, Chen M. Factors Influencing the Recurrence Potential of Benign Endometrial Polyps after Hysteroscopic Polypectomy. PLOS ONE. 2015;10(12):e0144857.

4. Anastasiadis PG, Koutlaki NG, Skaphida PG, Galazios GC, Tsikouras PN, Liberis VA. Endometrial polyps: prevalence, detection, and malignant potential in women with abnormal uterine bleeding. Europ J Gynecol Oncol 2000; 21:180-3.

5. Nijkang N, Anderson L, Markham R, Manconi F. Endometrial polyps: Pathogenesis, sequelae and treatment. SAGE Open Medicine. 2019;7:205031211984824.

6. Goldstein S, Monteagudo A, Popiolek D, Mayberry P, Timor-Tritsch I. Evaluation of endometrial polyps. American Journal of Obstetrics and Gynecology. 2002;186(4):669-674.

7. Kanthi J. Clinical Study of Endometrial Polyp and Role of Diagnostic Hysteroscopy and Blind Avulsion of Polyp. Journal of clinical and diagnostic research. 2016;.

8. Peterson W., Novak E. Endometrial Polyps. Obstetrical & Gynecological Survey. 1957;12(2):264-269.

9. Tyagi S, Manchanda R, Kulkarni S, Gupta M. Giant endometrial polyp protruding from the external cervical os-a case report. International Journal of Current Advanced Research. 2017;6(5):3989-3992.

10. Çil A, Bozkurt M, Kara D, Guler B. Giant endometrial polyp protruding from the external cervical os in a postmenopausal woman: magnetic resonance imaging and hysteroscopic findings. Proceedings in Obstetrics and Gynecology. 2013;3(3):1-9.

11. Wang J, Zhao J, Lin J. Opportunities and Risk Factors for Premalignant and Malignant Transformation of Endometrial Polyps: Management Strategies. Journal of Minimally Invasive Gynecology. 2010;17(1):53-58.

12. Labrie F, Bélanger A, Luu-The V, Labrie C, Simard J, Cusan L et al. Gonadotropin-Releasing Hormone Agonists in the Treatment of Prostate Cancer. Endocrine Reviews. 2005;26(3):361-379.

13. Steingold KA, Cedars M, Lu JK, Randle D, Judd HL, Meldrum DR. Treatment of endometriosis with a long-acting gonadotropin-releasing hormone agonist. Obstet Gynecol 1987; 69: 403

14. Hodgson, Ruth, et al. "GnRH Agonists for Uterine Fibroids." Cochrane Database of Systematic Reviews, 2017, doi:10.1002/14651858.cd012846.

15. Cupino-Arcinue, D, Tan-Espiritu, MRP. Novel use of GnRH agonist as neoadjuvant treatment for giant endometrial polyps.

16. Lin, Yu-Hung, et al. "An Adenomyomatous Polyp Presenting as a Large Hypervascular Tumor and Its Response to a Gonadotropin-Releasing Hormone Agonist." Taiwanese Journal of Obstetrics and Gynecology, vol. 52, no. 1, 2013, pp. 129–130., doi:10.1016/j.tjog.2013.01.016.

17. Vercellini P, Perino A, Consonni R, Trespidi L, Parazzini F, Giorgio P. Treatment with a gonadotrophin releasing hormone agonist before endometrial resection: a multicentre, randomised controlled trial. BJOG: An International Journal of Obstetrics and Gynaecology. 1996;103(6):562-568.

18. Kumar P, Sharma A. Gonadotropin-releasing hormone analogs: Understanding advantages and limitations. Journal of Human Reproductive Sciences. 2014;7(3):170.

The 10th Congress of the Asia Pacific Initiative on Reproduction
BRIDGING THE GAP: FERTILITY AND REPRODUCTION