Using Traditional Chinese Medicine Qi Moving, Stasis Dispelling, and Blood Cooling Therapy for Dysmenorrhea Caused by Adenomyosis：A Case Report

Chang Hsin-Huei [1,2] Su Shan-Yu[1,2]

[1]School of Post-baccalaureate Chinese Medicine, China Medical University, Taichung, Taiwan
[2]Department of Chinese Medicine, China Medical University Hospital, Taichung, Taiwan.

INTRODUCTION

Uterus adenomyosis is a common gynecological disorder characterized by the presence of endometrial glands and stroma within the myometrium associated with myometrial hypertrophy and hyperplasia[1]. Women with symptomatic adenomyosis present with uterine enlargement, heavy menstrual bleeding, and painful menses[2]. A role for adenomyosis in causing infertility and early miscarriage has been suggested[1].

The natural history, prevalence, and risk factors of adenomyosis are uncertain because the definitive diagnosis can only be made on pathology evaluation, typically the following hysterectomy, although a clinical diagnosis can be made with imaging studies. Thus, much that we know about the epidemiology of adenomyosis may, in fact, be the epidemiology of hysterectomy. It is generally estimated that adenomyosis is present in 20 to 35 percent of women in histological series post hysterectomy[1,2].

In terms of age of onset and progression of the disease, adenomyosis has been found in adolescents in studies that use pelvic imaging rather than a hysterectomy for diagnosis[3]. Most women undergoing a hysterectomy for adenomyosis are in their later reproductive years.

Adenomyosis often coexists with other uterine diseases, primarily uterine leiomyomas and endometriosis, and this makes it difficult to determine whether adenomyosis has unique risk factors or even how it behaves like a disease. As an example, the persistence of pelvic pain following optimal endometriosis surgical therapy may be confounded by the presence of adenomyosis[4].

Several additional studies have reported that prior uterine surgery may be a risk factor for adenomyosis[5,6].

In Chinese medicine, endometriosis is considered a “blood stasis syndrome” which results in the formation of endometriotic lesions[7]. In this case report, a Chinese herbal formula was designed to resolve blood stasis. We used the formula to alleviate the endometriosis-related symptoms.

CASE REPORT

A 46-year-old married woman who has been suffered from menstrual cramps in her lower abdomen for 35 years visited our traditional Chinese Medicine (TCM) clinic for help.

She underwent left ovarian cystectomy and myomectomy 23 years ago. Dysmenorrhea was worsened in the past three months. When she sought treatment at our TCM clinic on December 17, 2018, she was in her pre-ovulation phase. Her CA-125 value was 83.5 U/mL and the ultrasound image revealed a uterus with a corpus size of 8.22x7.22 cm. Meanwhile, there were ten myomas, the biggest of which was 3.70 x 2.72 cm in size.

METHOD

The treatment principles were moving qi, dispelling stasis, and, cooling blood. Scientific Chinese medication (powdered) was used. The prescriptions were Huang Qi 1g, Yan Hwu Suo 1g, Pu Huang 1g, Wu Ling Zhi 1g, Ru Xiang 0.5g, Mo Yao 0.5g, Xie Jie 0.15g, Chi Shao 1g, Shiuh Duan 1g, single-dose, twice daily. The formula was taken from the 5th day of a menstrual period until the last day of the same cycle. Since Pu Huang, Wu Ling Zhi, Ru Xiang, Mo Yao, Xie Jie, which dispel blood stasis may cause menorrhagia, we temporarily suspension of the formula on the period day1 to day5.

Result

After treatment for three months, her CA-125 level decreased to 77.3 U/mL, and the ultrasound revealed a decrease in the corpus size to 7.83 x 6.57 cm and the biggest myoma size to 3.50 x 2.91 cm. Meanwhile, menstrual pain in the lower abdomen was alleviated.

On June 12, 2020, she came to our TCM clinical again for further treatment. The same formula was prescribed. After treatment for two months, her CA-125 level decreased to 33.3 U/mL, and the ultrasound revealed a decrease in the corpus size to 7.89 x 5.90 cm and the biggest myoma size to 2.79 x 2.34 cm (see Table 1, Figure 1). Menstrual pain in the lower abdomen was subsided.

Table 1. Comparison of CA-125, corpus, and myoma size before and after treatment

	12/21/2018	04/02/2019	09/26/2020
CA-125 (U/mL)	83.5	77.3	33.3
Corpus size (cm)	8.22 x 7.22	7.83 x 6.57	7.89 x 5.90
Maximal myoma size (cm)	3.70 x 2.72	3.50 x 2.91	2.79 x 2.34

Figure 1. Comparison of ultrasound findings before and after treatment

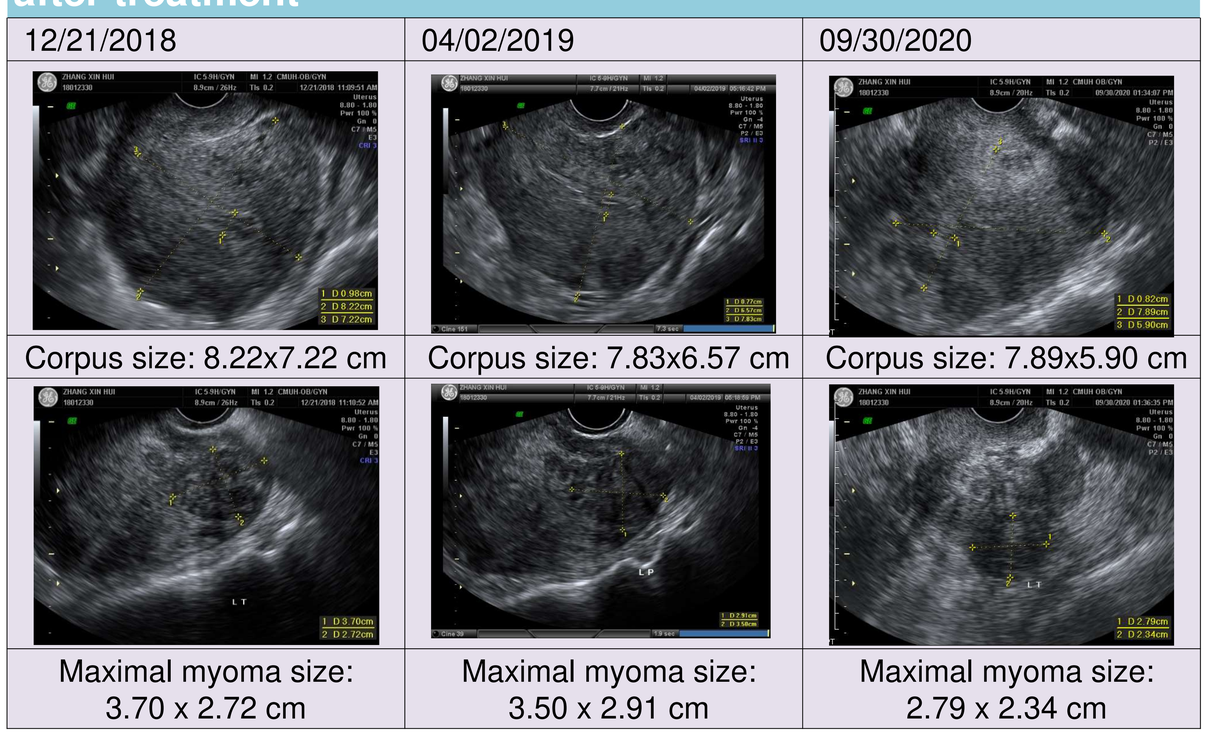

CONCLUSION

The formula we used is modified from Wenshen Xiaozheng Tang (WXT) which diminishes the expression of NF-κB regulates gene products involves in apoptosis and migration, including c-IAP1, c-IAP2, XIAP, survivin, Mcl-1, COX-2, and MMP-9 in ectopic endometriotic cells indicates that WXT induces apoptosis and inhibits migration of ectopic endometriotic stromal cells[7,8]. However, the therapeutic effect needs clinical trials to confirm.

Treatments for adenomyosis have been aimed at managing symptoms and improving fertility options. Management by hysterectomy is not always desired by women. Traditional Chinese medication for the treatments of adenomyosis is widely used in the Chinese population, where these treatments improve patient symptoms effectively, although large-scale studies have not yet been completed. Natural compounds, along with complementary and alternative medicines, are significant because of their multi-target characteristics, which provide new sources for difficult and chronic disease. We believe that traditional Chinese medicine will be one of the directions for future drug development in adenomyosis treatment.

REFERENCES

1. Abbott JA. Adenomyosis and Abnormal Uterine Bleeding (AUB-A)-Pathogenesis, diagnosis, and management. Best Pract Res Clin Obstet Gynaecol. 2017 Apr;40:68-81. doi: 10.1016/j.bpobgyn.2016.09.006. Epub 2016 Sep 30. PMID: 27810281.
2. Vercellini P, Viganò P, Somigliana E, Daguati R, Abbiati A, Fedele L. Adenomyosis: epidemiological factors. Best Pract Res Clin Obstet Gynaecol. 2006 Aug;20(4):465-77. doi: 10.1016/j.bpobgyn.2006.01.017. Epub 2006 Mar 24. PMID: 16563868.
3. Dietrich JE. An update on adenomyosis in the adolescent. Curr Opin Obstet Gynecol. 2010 Oct;22(5):388-92. doi: 10.1097/GCO.0b013e32833cefaf. PMID: 20613517.
4. Parker JD, Leondires M, Sinaii N, Premkumar A, Nieman LK, Stratton P. Persistence of dysmenorrhea and nonmenstrual pain after optimal endometriosis surgery may indicate adenomyosis. Fertil Steril. 2006 Sep;86(3):711-5. doi: 10.1016/j.fertnstert.2006.01.030. Epub 2006 Jun 16. PMID: 16782099.
5. Taran FA, Weaver AL, Coddington CC, Stewart EA. Understanding adenomyosis: a case control study. Fertil Steril. 2010 Sep;94(4):1223-1228. doi: 10.1016/j.fertnstert.2009.06.049. Epub 2009 Jul 30. PMID: 19643403; PMCID: PMC3150965.
6. Panganamamula UR, Harmanli OH, Isik-Akbay EF, Grotegut CA, Dandolu V, Gaughan JP. Is prior uterine surgery a risk factor for adenomyosis? Obstet Gynecol. 2004 Nov;104(5 Pt 1):1034-8. doi: 10.1097/01.AOG.0000143264.59822.73. PMID: 15516398.
7. Zhang Z, Cheng X, Gui T, Tao J, Huang M, Zhu L, Luo M, Cao P, Wan G. Wenshen Xiaozheng Tang induces apoptosis and inhibits migration of ectopic endometriotic stromal cells. J Ethnopharmacol. 2016 Dec 24;194:386-394. doi: 10.1016/j.jep.2016.07.019. Epub 2016 Jul 9. PMID: 27401290.
8. Weilin Zheng, Lixing Cao, Zheng Xu, Yuanyuan Ma, Xuefang Liang, "Anti-Angiogenic Alternative and Complementary Medicines for the Treatment of Endometriosis: A Review of Potential Molecular Mechanisms", Evidence-Based Complementary and Alternative Medicine, vol. 2018, Article ID 4128984, 28 pages, 2018. https://doi.org/10.1155/2018/4128984

CONTACT

Correspondence to Dr. Su Shan-Yu, Department of Chinese Medicine, China Medical University Hospital, Tel:886-4-22052121 ext.4561; E-mail: shanyusu@gmail.com

The 10th Congress of the Asia Pacific Initiative on Reproduction
BRIDGING THE GAP: FERTILITY AND REPRODUCTION